

Chapter 39

Lifetime Experiences and Where We are Going: Chiari I with Syringohydromyelia—Controversies and Development of Decision Trees

Arnold H. Menezes, M.D., Jeremy D.W. Greenlee, M.D., and Kathleen A. Donovan, A.R.N.P.

The hindbrain herniation syndrome (51), often referred to as the Chiari I malformation, is a disorder that has traditionally been defined as a downward herniation of the cerebellar tonsils through the foramen magnum (8, 9, 36). The extent of tonsillar herniation is recognized as being more than 4 to 5 mm below the plane of foramen magnum on sagittal magnetic resonance images (11, 13, 28, 30, 33, 38). This anomaly is associated with syringohydromyelia in 45 to 68% of cases (17, 30, 38). It occurs in conjunction with osseous abnormalities of the craniovertebral junction (12, 16, 22, 24, 25, 30, 42, 43, 49). This is distinguished from the more familiar Chiari II malformation, which is present at birth and consists of downward herniation of the cerebellum and medulla into the spinal canal in association with complex anomalies such as aqueductal forking, polymicrogyria, and myelodysplasia (7). It is now felt that the Chiari I malformation, or the hindbrain herniation, is inherently different from the Chiari II malformation. The Chiari I occurs sporadically, and there is no inherent nervous system abnormality except for that which is the result of crowding of the posterior fossa, which predisposes to the hindbrain herniation (21, 27, 30, 33). Changes in cerebrospinal fluid (CSF) dynamics contribute to the symptoms and the clinical syndrome characterized by occipital Valsalva-type headaches, lower cranial nerve abnormalities, and a spinal cord myelopathy that may be overshadowed by the syringohydromyelia.

The hindbrain herniation syndrome—“Chiari I malformation”—has achieved significant interest with the advent of magnetic resonance imaging (MRI). This has revolutionized the diagnosis and led to early detection in situations that otherwise would not have been recognized or misdiagnosed. Thus, there is a significant need for a greater understanding of the pathology, the genesis, and manifestations of the syndrome, as well as the need for outcome studies.

In the early 1970s, the diagnosis was difficult. The clinical suspicion had to be supported by plain radiographs and myelography carried up to the posterior fossa. This was at times supplemented with vertebral angiography to recognize the position of the posterior inferior cerebellar artery and the cerebellar tonsils. Gas myelography complemented this with pleuridirectional polytomography (27). The advent of computed tomography (CT) brought about the use of Iohexol to opacify the subarachnoid spaces and the subsequent use of delayed CT to identify the syrinx. By this time, there were several explanations for this latter phenomenon (1, 4, 27). MRI with its current refinement has allowed for an immediate diagnosis and a more urgent need for the proper management of these patients. Our interest at the craniocervical junction automatically led to the neural abnormalities and the Chiari malformation database. This is a prospective study, and the analysis of this accumulation of 639 patients from 1978 to 2004 is presented here in a concise form. This is the work of a single surgeon (AHM) with documentation and subsequent archive retrieval to present a treatment algorithm, which has stayed stable since its first proposal in 1988 (10).

In a recent comprehensive review of a large series of 364 symptomatic patients with Chiari I malformation, Milhorat et al. (30) found an associated syringohydromyelia in 65% of cases, scoliosis in 42%, abnormal retroflexed odontoid

process in 26%, and basilar invagination in 12%. Similar incidences were identified by us in 1980 and subsequently in 1988 and 1999 (10, 11, 25). Several other authors have commented about this, thus the importance of a prospective database. A number of important features have been recognized as a result of this documentation and will be presented here, briefly. There is a definite need to understand abnormalities associated with the Chiari I malformation because they affect the manner in which treatment is proposed (26). Of concern has been the operation for bony posterior fossa decompression without a duraplasty or intradural dissection (17, 19, 20). The literature had been replete with patient subjective improvement followed by a decline in function within 2 to 3 years in about 30% of patients who had undergone a bony posterior fossa decompression alone without anything being done to the dura (27). Also, it became important to recognize that long-term results were required to be reviewed rather than any report with less than 3 years follow-up. Failure to improve symptoms as well as documented regression of the syrinx requires careful investigation of the operative procedure performed and the associated abnormalities. Other questions that needed to be answered were the differences in childhood and adult presentation. An early attempt to identify prognostic factors was published in 1989 (10) and still holds true. Thus, it is only a long-term study that can provide information into the outcome because no laboratory studies can mimic this.

FACTORS DETERMINING SURGICAL TREATMENT

- Bony craniovertebral junction abnormalities: these may consist of retroflexed upwardly migrated odontoid process, basilar invagination, paramesial invagination, and the congenital malformations with proatlax segmentation failures (16, 22–24, 30, 49).
- Bone disease: Two examples of bone disease are osteogenesis imperfecta and the Hadju-Cheney syndrome (12, 30, 31, 42). This has provided significant insight into the acquired form of a hindbrain herniation with formation of syrinx. Diseases such as achondroplasia that cause narrowing at the foramen magnum and thus crowding in the posterior fossa are now being identified as an ongoing compendium of changes that occur at the foramen magnum as a result of the osteochondral abnormalities.
- Instability at the craniocervical junction: this has a significance in the fact that the craniocervical instability may exist by itself or as a result of 1) atlas assimilation with segmentation failures of the second and third cervical vertebra or 2) the syringohydromyelia extending into the upper cervical canal leading to changes in the upper cervical plexus innervation and thus weakness of the strap muscles of the neck. Instability would then occur with a posterior fossa and upper cervical decompression. The cantilever effect of the large head with a weak fulcrum of the neck can lead to potentiation of instability and deficits (17, 23).
- Syringohydromyelia and syringobulbia: All patients (n = 22) with syringobulbia had syringohydromyelia.
- The position of the cerebellar tonsils and the posterior inferior cerebellar artery, especially in patients with basilar migraine (38): this occurred in 25% of our patients, where the vessels were sandwiched between the cervicomedullary junction and the impacted tonsils.
- Previous surgical procedures: their affect on scarring, previous aseptic meningitis, or bacterial infections and, more important, whether CSF lumbar drainage was used after surgery to avoid a CSF leak from the wound.
- The identification of abnormal CSF dynamics: the important finding of hydrocephalus required shunting. The presence of abnormal CSF dynamics was investigated via myelography and presently CSF motion studies on MRI (2, 4, 5, 35, 38, 45, 52).

NEURODIAGNOSTIC IMAGING

The diagnostic studies performed reflected the development of neuroimaging with pleuridirectional tomography,

myelotomography using pleuridirectional tomography, CT and subsequently MRI, and the appreciation of CSF dynamics in the last 10 years. Dynamic studies of flexion, extension, and the effects of cervical traction were performed in patients in whom instability was suspected. All operative procedures were recorded as far as the pathology, the location of the tonsils and the fourth ventricle, presence of vascular abnormalities, and the patency of the fourth ventricle with possible communication into the central canal and syringohydromyelia. A photographic record of this was maintained. Follow-up consisted of MRI at 3 months and at the end of 1 year. A yearly neurological examination has been maintained.

Chapter 39, Lifetime Experiences and Where We are Going: Chiari I with Syringohydromyelia—Controversies and Development of Decision Trees (continued)

SURGICAL CONCERNS

- **Hydrocephalus:** The presence of hydrocephalus required placement of a diversionary procedure such as with ventriculoperitoneal shunting (11, 17, 24). We have not offered third ventriculostomy because of the need for consistent deflation of the ventricles as well as displacement of the cerebellar tonsils.
- **Approach:** The presence of a craniovertebral abnormality with ventral compression mandated a ventral decompression (23, 25). Otherwise, a posterior fossa decompression was made. We felt it important to recognize the need for decompression, mainly at foramen magnum, rather than in the posterior fossa to avoid the concern of cerebellar slump (18, 27). The other feature of interest was the need to perform cervical laminectomies. For Chiari I malformation, we have limited the operative procedure to removal of only the superior three fourths of the posterior atlas arch. Intradural lysis of adhesions with shrinkage of the cerebellar tonsils permitted limited cervical laminectomy (14, 24, 38).
- **Dural incision:** The question of whether or not an intradural procedure should be made has been answered with the fact that all patients who underwent an operation with associated syringohydromyelia required the intradural procedure. Our findings of intradural pathology would not have been recognized if the dura had been left intact. The surgical concerns of relocating the posterior inferior cerebellar vessels out of the fourth ventricle, shrinkage of the cerebellar tonsils, and whether or not an obex plug should be made have to be answered. Earlier on in the series, the obex plug was made using a strip of cervical muscle. Our early presentation showed a satisfactory result with this (10). Subsequently, this was rescinded because it was felt to be superfluous (39, 40). Regarding a duraplasty, the cervical fascia was harvested at the time of the initial portion of the procedure and used for the duraplasty.
- **Fusions:** Approximately 8% of our patients had a reducible instability without craniovertebral junction (CVJ) abnormalities. The reason for this was previously mentioned.
- **Presence of syringohydromyelia or syringobulbia:** If the syringohydromyelia was present in the face of a ventral bony abnormality at the foramen magnum, such as basilar invagination, an anterior decompression of the CVJ was first made. In such a circumstance, the dura was left intact when the posterior fossa decompression was made at the dorsal occipitocervical fusion. A fourth ventricle to subarachnoid shunt was installed with syringohydromyelia patients only in the face of scarring or reoperation.

CHIARI I MALFORMATION TREATMENT ALGORITHM

Table 39.1 refers to the treatment algorithm for Chiari I malformations, as adapted from the craniovertebral junction abnormalities. The first item considered is the presence of hydrocephalus. Twenty-five patients underwent ventriculoperitoneal shunting, with complete resolution of symptoms in eight. Seventeen of the 25 had no improvement of their Chiari symptoms and underwent a posterior decompression.

In those patients in whom hydrocephalus was not seen, the presence of craniovertebral junction abnormality and ventral compression was the next factor. Two hundred seventy-six patients had a ventral abnormality. They were reducible in 41 of the 276 patients. In this situation, a posterior fossa procedure as outlined was performed, as was a dorsal occipitocervical fixation. In the irreducible craniovertebral junction abnormalities with an associated hindbrain herniation, ventral decompression was made first followed by the posterior fossa decompression and fusion.

A Chiari I malformation was present in 363 patients without any evidence of craniovertebral junction bony abnormalities. Syringohydromyelia was associated with 246 of these 363 patients. In these individuals, a posterior fossa decompression was made. The tonsillar shrinkage was accomplished, and before a duraplasty, a fourth ventricle to subarachnoid shunt was installed up until 1992. Subsequent to that, we have not placed an internal shunt unless there was significant scarring from either a previous operative procedure or from previous meningitis. Posterior fossa decompression and duraplasty were made in the remaining 117 patients.

Study Analysis

Six hundred thirty-nine patients underwent operation by the senior author. Of these, 201 were in the 1 to 16 years of age group. Of the 276 patients with craniovertebral junction abnormalities associated with a Chiari I malformation, 80 were children, and 46% had associated syringohydromyelia. In 363 patients with Chiari I malformation without craniovertebral junction abnormalities, 121 were in children. Of this group, a syrinx was present in 68%. Of the total 639 patients, 96 had undergone a previous posterior fossa decompression procedure.

In reviewing the 373 patients with Chiari I malformation without bony abnormalities, a syringobulbia was present in 14. Syringomyelia was present in 246 patients. In those patients in whom the posterior fossa bony abnormality was associated with a Chiari malformation and syrinx, the syringohydromyelia resolved with the ventral decompression alone.

Results of Surgical Treatment

The follow-up has been 1 to 26 years. The factors taken into consideration for determining their surgical efficacy have been previously outlined (11). A normal examination was found after surgery in 30% of the patients without any neurological symptoms or signs of their previously existing disease. Sixty-five percent of patients showed marked improvement except for one parameter. Two percent had deterioration over 30 months, and 3% were unchanged and developed new symptoms at the end of 3 years. In the patients who remained unchanged or had deterioration, a reexploration of the posterior fossa was made with improvement in 50%. This was found to be caused by scarring of the exit foramen of the fourth ventricle, displacement of a fourth ventricle to subarachnoid shunt, and the reformation of the exoccipital bone of the posterior fossa.

DATA ANALYSIS OF 363 PATIENTS WITH CHIARI I MALFORMATION WITHOUT CRANIOVERTEBRAL JUNCTION ABNORMALITIES

Findings that Influence Treatment and are Controversial

Instability

Instability was present in 8% of patients. In all such individuals, a cervicothoracic brace was prescribed at the time of initial diagnosis with improvement in some of the symptomatology. The operative procedure used a limited posterior fossa decompression and thus had the ability to provide an associated occipitocervical fusion (Fig. 39.1). These patients had marked regression of their symptoms. Eight of the 29 patients had undergone a previous posterior fossa operative procedure, and in 16, the instability was also caused by dehiscence of the muscle closure (37).

Reduction in Posterior Fossa Volume

Quantitative measurements of the posterior fossa volume were made (3, 6, 17, 21, 31, 33, 34, 46). The MRI findings were tonsillar herniation of more than 6 mm below the plane of the foramen magnum and consistently reduced or absent CSF spaces in the posterior and lateral aspect of the cerebellum. There was a marked difference between the posterior fossa volumes in the affected individuals compared with an average volume of control participants. There was no correlation with the sagittal diameter of the posterior fossa but rather in the basion-peak of the tentorium cerebelli distance, which was considerably shorter in patients with the Chiari I malformation as compared with the controls (17). Milhorat et al. (30) performed similar volumetric calculations for posterior cranial fossa and demonstrated a significant reduction of the total volume and a 40% reduction of CSF volume with normal brain volume. Thus, the current evidence suggests that the Chiari I malformation disorder is one of mesoderm, and the displacements of CSF contribute to the characteristic clinical syndrome (Fig. 39.2).

Analysis of Chiari I Malformation Presentation in Children Younger than 6 Years

The goals of this detailed evaluation were to identify patterns of presentation, aid an early diagnosis, and enhance the education of health care providers (16). Forty-five children were identified, 24 younger than 3 years. Of these 45 children, 10 had undergone previous operative procedures for Chiari I malformation. Six patients had undergone previous Nissen fundoplication or gastrostomy before the diagnosis of the Chiari I malformation. Two individuals had previous tracheostomies before diagnosis.

Repeated aspiration pneumonia was recognized in 25% and headaches in 50% (38, 50). The conclusions with the study comparing children younger than 3 years and those between 3 and 6 years of age showed oropharyngeal dysfunction presentation in 66% of those younger than 3 years and only 8% of those between 3 and 6 years (17, 47). However, scoliosis was present in 52% of children older than 3 years and only in 12% in those younger than 3 years (Fig. 39.3) (17, 32). Syringohydromyelia was present in 96% of patients between the ages of 3 and 6 years, whereas in only 16% in patients younger than 3 years.

Association of Syringobulbia with Syringohydromyelia

Syringobulbia was present in 3.8% of patients, whereas syringomyelia was present in 68% of the total number of patients. In all individuals with syringobulbia, a syringohydromyelia was evident but did not communicate with the fourth ventricle. The syringohydromyelia of the cervical cord extended as a cavitation upward, either paralleling or digressing from the fourth ventricle plane with entry then into it (Fig. 39.4). The syringobulbia resolved with the syringohydromyelia with the posterior fossa surgical procedure. The syringobulbia was a separate entity from the

fourth ventricle documented at the time of operation.

Operative Findings in 363 Patients with Chiari I Malformations (121 Children)

- The cerebellar tonsils occupied the cavity of the fourth ventricle in 95 of 363 patients (Fig. 39.5). Failure to recognize this with mere bony decompression would have led to unsatisfactory results.
- Scarring of the outlet to the fourth ventricle was seen in 17%. The presence of syringohydromyelia with communication into the fourth ventricle on MRI was the clue. Mild tonsillar ectopia was also seen in these individuals. The scarring required fourth ventricle to subarachnoid shunt with resolution of the symptoms (Fig. 39.6).
- Vascular abnormality with presence of the posterior inferior cerebellar artery branches within the fourth ventricle was evident in 22% of patients. A presentation of basilar migraine was seen in all of these individuals (Fig. 39.7). The branches of the posterior inferior cerebellar artery were mobilized to come out of the fourth ventricle by shrinkage of the tonsils and maintaining the arachnoid adhesions between the tonsils and the vascular loop, thus ensuring that the tonsils and vessel loop stayed outward. The headaches in these individuals were described as with classic migraine and abnormalities in homonymous visual fields. The symptoms resorbed after posterior fossa surgery.
- Connection of the fourth ventricle with the cervical central canal, despite the fact that MRI only visualized 18 to 20% of this connection, was seen in 196 of 363 patients. During surgery, a right angle probe was passed through the obex toward the central canal for a distance of approximately 12 to 14 mm. This was definitely more than that which was normally seen otherwise. The only explanation is that severe crowding at foramen magnum with the tonsillar ectopia may have prevented the visualization of this connection on preoperative MRI (15,29).
- The foramen of Magendie was obstructed by an arachnoid veil in 26 of 363 patients (Fig. 39.8). Thus, 7.4% of patients had partial occlusion to the outflow of CSF through the fourth ventricle. No hydrocephalus was detected in these individuals, but they all had syringohydromyelia. We agree with the hypothesis of Tubbs et al. (48) The distinct veils could represent remnants of the rhombic lip, as described. Unlike the description by Rifkinson-Mann et al.(41), these veils at foramen of Magendie were not associated with hydrocephalus.

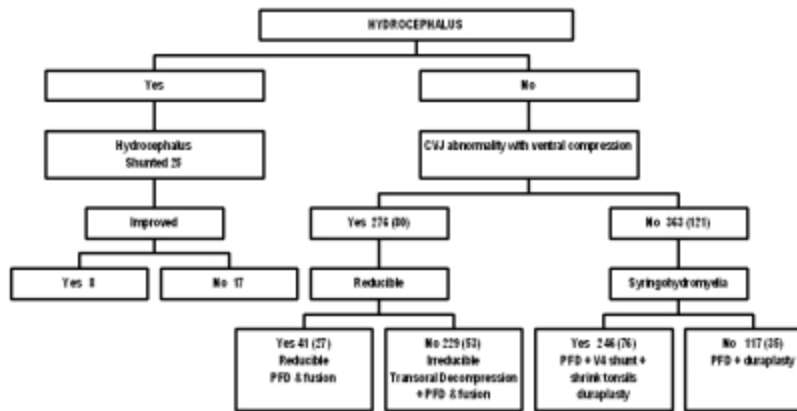
CONCLUSION

We have reviewed the database of 639 patients who underwent surgery between 1978 and 2004. The factors that have been taken into consideration in planning surgical treatment have been described with the treatment algorithm. The controversial findings described aided in a surgical physiological decision tree for management of these symptomatic patients.

Our conclusions are 1) obex plug is unnecessary, 2) an irreducible posterior fossa pathology requires decompression and subsequent fusion, 3) reducible bony abnormality with Chiari I malformation requires posterior fossa decompression and fusion, 4) Chiari I malformation with syringohydromyelia should have an intradural procedure with duraplasty, and 5) a primary syrinx shunt for Chiari malformation with syringohydromyelia has no role in management (44).

Chapter 39, Lifetime Experiences and Where We are Going: Chiari I with Syringohydromyelia—Controversies and Development of Decision Trees (continued)

TABLE 39.1. Chiari malformation treatment algorithma



(click on table for full-size image)

REFERENCES

1. Aboulker J: La syringomyelia et les liquids intra-rachidiens. **Neurochirurgie** 25:9–144, 1979.
2. Armonda RA, Citrin CM, Foley KT, Ellenbogen RG: Quantitative cine-mode magnetic resonance imaging of Chiari I malformations: An analysis of cerebrospinal fluid dynamics. **Neurosurgery** 35:214–224, 1994.
3. Badie B, Mendoza D, Batzdorf U: Posterior fossa volume and response to suboccipital decompression in patients with Chiari I malformation. **Neurosurgery** 37:214–218, 1995.
4. Ball MJ, Dayan AD: Pathogenesis of syringomyelia. **Lancet** ii:799–801, 1972.
5. Batzdorf U: Chiari I malformation with syringomyelia. Evaluation of surgical therapy by magnetic resonance imaging. **J Neurosurg** 68:726–730, 1988.
6. Batzdorf U: Pathogenesis and development theories, in Anson JA, Benzel EC, Awad IA (eds): *Syringomyelia and the Chiari Malformations*. Park Ridge, American Association of Neurological Surgeons, 1996, pp 35–46.
7. Cai C, Oakes WJ: Hindbrain herniation syndromes: The Chiari malformations (I and II). **Semin Pediatr Neurol** 4:179–191, 1997.
8. Chiari H: Über Veränderungen des Kleinhirns, des pons und der medulla oblongata. Folge von congenitaler hydrocephalie des grossherns. **Deskschr Akad Wiss Wien** 63:71–116, 1895.
9. Cleland J: Contribution to the study of spina bifida, encephalocele and anencephalys. **J Anat Physiol** 17:257–291, 1883.
10. Dyste GN, Menezes AH: Presentation and management of pediatric Chiari malformations without myelodysplasia. **Neurosurgery** 23:589, 1988.

11. Dyste GN, Menezes AH, VanGilder JC: Symptomatic Chiari malformations: An analysis of presentation, management and long-term outcome. **J Neurosurg** 71:159–168, 1989.
12. Elisevich K, Fontaine S, Bertrand G: Syringomyelia as a complication of Paget's disease. **J Neurosurg** 67:611–613, 1987.
13. Elster AD, Chen MY: Chiari I malformations: Clinical and radiologic reappraisal. **Radiology** 183:347–353, 1992.
14. Fischer EG: Posterior fossa decompression for Chiari I deformity, including resection of the cerebellar tonsils. **Childs Nerv Syst** 11:625–629, 1995.
15. Gardner WJ, Angel J: The mechanism of syringomyelia and its surgical correction. **Clin Neurosurg** 6:131–140, 1959.
16. Greenlee JDW, Donovan KA, Hasan DM, Menezes AH: Chiari I malformation in the very young child: The spectrum of presentations and experience in 31 children under age 6 years of age. **Pediatrics** 110:1212–1219, 2002.
17. Greenlee J, Garell PC, Stence N, Menezes AH: Comprehensive approach to Chiari malformation in pediatric patients. **Neurosurg Focus** 6:Article 4, 1999.
18. Holly LT, Batzdorf U: Management of cerebellar ptosis following craniovertebral decompression for Chiari I malformation. **J Neurosurg** 94:21–26, 2001.
19. Isu T, Iwasaki Y, Akino M, Abe H: Hydrosyringomyelia associated with a Chiari I malformation in children and adolescents. **Neurosurgery** 26:591–591, 1990.
20. Krieger MD, McComb JG, Levy ML: Toward a simpler surgical management of Chiari I malformation in a pediatric population. **Pediatr Neurosurg** 30:113–121, 1999.
21. Marin-Padilla M: Notochordal-basichondrocranium relationships: Abnormalities in experimental axial skeletal (dysraphic) disorders. **J Embryol Exp Morphol** 53:15–38, 1979.
22. McRae DL: The significance of abnormalities of the cervical spine: Caldwell lecture 1959. **AJR Am J Roentgenol** 84:3–25, 1960.
23. Menezes AH: Chiari I malformations and hydromyelia: Complications. **Pediatr Neurosurg** 17:146–154, 1991–1992.
24. Menezes AH: Craniovertebral anomalies and syringomyelia, in Choux M, Di Rocco C, Hockley A, Walker M (eds): *Pediatric Neurosurgery*. London, Churchill Livingstone, 1999, pp 151–184.

25. Menezes AH: Craniovertebral junction abnormalities with hindbrain herniation and syringomyelia: Regression of syringomyelia after excision of ventral craniovertebral compression, in Tamaki N, Batzdorf U, Nagashima T (eds): *Syringomyelia*. Tokyo, Springer-Verlag, 2001, pp 136–146.
26. Menezes AH: Primary craniovertebral anomalies and the hindbrain herniation syndrome (Chiari I): Data base analysis. **Pediatr Neurosurg** 23:260–269, 1995.
27. Menezes AH, Smoker WRK, Dyste GN: Syringomyelia, Chiari malformations and hydromyelia, in Youmans JR (ed): *Neurological Surgery*. Philadelphia: W.B. Saunders Co., 1990, pp 1421–1459.
28. Mikulis DJ, Diaz O, Eggin TK, Sanchez R: Variance of the position of the cerebellar tonsils with age: Preliminary report. **Radiology** 183:725–728, 1992.
29. Milhorat TH, Capocelli AL Jr, Anzil AP, Kotzen RM, Milhorat RH: Pathological basis of spinal cord cavitation in syringomyelia: Analysis of 105 autopsy cases. **J Neurosurg** 82:802–812, 1995.
30. Milhorat TH, Chou MW, Trinidad EM, Kula RW, Mandell M, Wolpert C, Speer MC: Chiari I malformation redefined: Clinical and radiographic findings for 364 symptomatic patients. **Neurosurgery** 44:1005–1017, 1999.
31. Milhorat TH, Miller JI, Johnson WD, Adler DE, Heger IM: Anatomical basis of syringomyelia occurring with hindbrain lesions. **Neurosurgery** 32:748–754, 1993.
32. Muhonen M, Menezes AH, Sawin P, Weinstein S: Scoliosis in pediatric Chiari malformations without myelodysplasia. **J Neurosurg** 77:69–77, 1992.
33. Nishikawa M, Sakamoto H, Hakuba A, Nakanishi N, Inoue Y: Pathogenesis of Chiari malformation: A morphometric study of the posterior cranial fossa. **J Neurosurg** 86:40–47, 1997.
34. Nyland H, Krogness KG: Size of posterior fossa in Chiari type I malformation in adults. **Acta Neurochir (Wien)** 40:233–242, 1978.
35. Oldfield EH, Muraszko K, Shawker TH, Patronas NJ: Pathophysiology of syringomyelia associated with Chiari I malformation of the cerebellar tonsils. **J Neurosurg** 80:3–15, 1994.
36. Ollivier d'Anders CP: *De la Moelle Epinière et de ses Maladies*. Paris, Chex Crivot, 1824.
37. Pare LS, Batzdorf U: Syringomyelia persistence after Chiari decompression as a result of pseudomeningocele formation: Implications for syrinx pathogenesis—Report of three cases. **Neurosurgery** 43:945–948, 1998.
38. Park JK, Gleason PL, Madsen JR, Goumnerova LC, Scott RM: Presentation and management of Chiari I malformation in children. **Pediatr Neurosurg** 26:190–196, 1997.

39. Piper JG, Menezes AH: Chiari malformation in the adult, in Menezes AH, Sonntag VKH (eds): *Principles of Spinal Surgery*. New York, McGraw-Hill, 1996, pp 379–397.
40. Piper JG, Menezes AH: The relationship between syringomyelia and the Chiari malformations, in Awad IA, Benzel EC, Anson JA (eds): *Syringomyelia and the Chiari Malformations*. Park Ridge: American Association of Neurological Surgeons, 1996, pp 91–104.
41. Rifkinson-Mann S, Sachdev VP, Huang YP: Congenital fourth ventricular midline outlet obstruction: Report of two cases. **J Neurosurg** 67:595–599, 1987.
42. Sawin PD, Menezes AH: Basilar invagination in osteogenesis imperfecta and related osteochondrodysplasias: Medical and surgical management. **J Neurosurg** 86:950–960, 1997.
43. Schady W, Metcalfe RA, Butler P: The incidence of craniocervical bony anomaly in the adult Chiari malformation. **J Neurol Sci** 82:193–203, 1987.
44. Sgouros S, Williams B: A critical appraisal of drainage in syringomyelia. **J Neurosurg** 82:1–10, 1995.
45. Stoodley MA, Jones NR, Brown CJ: Evidence for rapid fluid flow from the subarachnoid space into the spinal cord central canal in the rat. **Brain Res** 707:155–164, 1996.
46. Stovner LJ, Bergan U, Nilsen G, et al: Posterior cranial fossa dimensions in the Chiari I malformation: Relation to pathogenesis and clinical presentation. **Neuroradiology** 35:113–118, 1993.
47. Tsou VM, Bishop PR: Gastroesophageal reflux in children. **Otolaryngol Clin North Am** 31:419–434, 1998.
48. Tubbs RS, Smyth MD, Wellons JC, Oakes WJ: Arachnoid veils and the Chiari I malformation. **J Neurosurg** 100:465–467, 2004.
49. Vega A, Quintana F, Berciano J: Basichondrocranium anomalies in adult Chiari type I malformation: A morphometric study. **J Neurol Sci** 99:137–145, 1990.
50. Weinberg JS, Freed DL, Sadock J, Handler M, Wisoff JH, Epstein FJ: Headache and Chiari I malformation in the pediatric population. **Pediatr Neurosurg** 29:14–18, 1998.
51. Williams B: On the pathogenesis of syringomyelia: A review. **J R Soc Med** 73:798–806, 1980.
52. Wolpert SM, Bhadelia RA, Bogdan AR, et al: Chiari I malformations: Assessment with phase-contrast velocity MR. **AJNR Am J Neuroradiol** 15:1299–1308, 1994.

Fig. 39.1 A, mid-sagittal T2-weighted MRI of craniocervical junction in the flexed position. Note the hindbrain herniation with tonsillar ectopia to the upper border of C2. There is a retroflexed odontoid process that indents into the ventral mid medulla. The cervicomedullary buckle is opposite the body of C2. B, mid-sagittal T2-weighted MRI in extension. There is marked reduction in the ventral bony indentation on the medulla. C,

postoperative cervical spine radiograph. A posterior fossa operative procedure was made for the Chiari malformation and a dorsal occipitocervical fixation accomplished with titanium loop instrumentation and rib graft. She had resolution of her neurological symptoms.

- FIG. 39.2 Mid-sagittal T1-weighted MRI of craniocervical junction to include the posterior fossa and upper cervical canal. Note the vertical upward migration of the clivus and craniocervical junction anteriorly. The clivus-odontoid articulation indents into the pontomedullary junction. The cerebellar ectopia extends down to the C3 level, and syringohydromyelia is evident. The vertical height of the posterior fossa has been markedly reduced, whereas the sagittal diameter from the tuberculum to the torcula is maintained.
- FIG. 39.3 A, mid-sagittal T1-weighted MRI of posterior fossa and cervical spine. A Chiari I malformation is seen with 18-mm descent of the cerebellar tonsils. A cervicothoracic syringohydromyelia is evident. Note the presence of a vascular flow void between the tonsil and the dorsal aspect of the medulla. B, frontal view of the cervicothoracic-lumbar spine. A thoracic scoliosis is evident. C, mid-sagittal T1-weighted MRI made 3 months after posterior fossa operative procedure. Note the upward migration of the cerebellar tonsils. The syrinx is very faintly seen. D, thoracic radiographs in the frontal plane. Note the correction of the thoracic scoliosis 6 months after the operative procedure for the Chiari malformation.
- FIG. 39.4 Composite of T2-weighted MRI in the coronal (*left*) and mid-sagittal plane (*right*). Note the presence of the cervical syringohydromyelia. This extends upward and parallels the floor of the fourth ventricle to reach the tegmentum of the mesencephalon. The syringobulbia is distinct from the fourth ventricle cavity. The tonsillar ectopia is evident.
- FIG. 39.5 A, mid-sagittal T1-weighted MRI of the posterior fossa and cervicothoracic spine. Note the significant descent of the cerebellar tonsil to the C2-3 interspace. The fourth ventricle seems to be in satisfactory position. There is a cervical syringohydromyelia that extends up to the floor of the fourth ventricle. B, operative view through microscope with the dura opened in the upper cervical canal and posterior fossa. The right cerebellar tonsil is being elevated out of the syrinx cavity and the floor of the fourth ventricle. C, operative view through microscope after shrinkage of the right cerebellar tonsil that occupied the fourth ventricle and the syringobulbia.
- FIG. 39.6 A, mid-sagittal T1-weighted MRI in a 40-year-old individual with weakness of the hands and right Charcot thumb. The mild tonsillar ectopia is visualized. The syrinx continues up to the fourth ventricle. B, operative view through microscope at posterior fossa and upper cervical exploration. There are significant adhesions and scarring between both cerebellar tonsils, and this occludes the fourth ventricle. C, operative photograph through the microscope with opening of the cavity of the fourth ventricle. D, operative photograph visualizing placement of a fourth ventricle to cervical subarachnoid shunt.

FIG. 39.7 Operative view through microscope. The dura has been opened. The cerebellar tonsils are spread apart to visualize the vermian branch of the posterior inferior cerebellar artery that occupies the fourth ventricle.

FIG. 39.8 Operative view through the microscope. The dura has been opened and the cerebellar tonsils separated to visualize a veil over the foramen of Magendie obstructing the outflow of the floor of the fourth ventricle.