



**Congress of
Neurological
Surgeons**

GUIDELINES

CONGRESS OF NEUROLOGICAL SURGEONS SYSTEMATIC REVIEW AND EVIDENCE-BASED GUIDELINE FOR THE MANAGEMENT OF PATIENTS WITH RESIDUAL OR RECURRENT NONFUNCTIONING PITUITARY ADENOMAS

Sponsored by

Congress of Neurological Surgeons (CNS) and the AANS/CNS Tumor Section

Endorsed by

Joint Guidelines Committee of the American Association of Neurological Surgeons (AANS)
and the Congress of Neurological Surgeons (CNS)

Jason Sheehan, MD, PhD¹, Cheng-Chia Lee, MD¹, Mary E. Bodach, MLIS², Luis M. Tumialan MD³,
Nelson M. Oyesiku, MD, PhD⁴, Chirag G. Patil, MD⁵, Zachary Litvack, MD⁶, Gabriel Zada, MD⁷,
Manish K. Aghi, MD, PhD⁸

¹ Department of Neurological Surgery, University of Virginia, Charlottesville, Virginia, USA

² Guidelines Department, Congress of Neurological Surgeons, Schaumburg, Illinois, USA

³ Barrow Neurological Institute, Phoenix, Arizona, USA

⁴ Department of Neurosurgery, Emory University, Atlanta, Georgia, USA

⁵ Department of Neurosurgery, Cedars-Sinai Medical Center, Los Angeles, California, USA

⁶ Department of Neurosurgery, George Washington University, Washington, DC, USA

⁷ Department of Neurological Surgery, University of Southern California, Los Angeles, Los Angeles, California, USA

⁸ Department of Neurosurgery, University of California, San Francisco, San Francisco, California, USA

Correspondence:

Jason Sheehan, MD, PhD
Department of Neurological Surgery
University of Virginia
P.O. Box 800212
Charlottesville, VA 22908
E-mail: jsheehan@virginia.edu

ABSTRACT

Background: Despite the advancement of microsurgical and endoscopic techniques, some nonfunctioning pituitary adenomas (NFPAs) can be difficult to cure. Tumor recurrence or incomplete resection may occur in some patients with NFPAs, and management strategies for these NFPAs remain unclear.

Objective: To review the existing literature as it pertains to the management of postsurgical residual or recurrent NFPAs.

Methods: A systematic review of the treatment options for residual or recurrent NFPAs was performed. In this review, the authors critically evaluated the evidence to support the options of repeat microsurgical resection, stereotactic radiosurgery (SRS), stereotactic radiotherapy (SRT), and fractionated radiation therapy (XRT).

Results: Forty-nine studies met the inclusion criteria for analysis: outcome of repeat surgical resection (n = 4), outcome of radiosurgery (ie, single session or hypofractionated SRS; n = 24), or fractionated radiotherapy (ie, conventional XRT, proton beam radiotherapy [PBRT], intensity modulated radiotherapy [IMRT], SRT; n = 21). No Class I evidence was available, 6 studies met criteria for Class II evidence, and other studies provided Class III evidence. A meta-analysis of 5 Class II studies with recurrence rates for both adjuvant radiation therapy and observation demonstrated that XRT for residual/recurrent NFPAs offered a lower rate of recurrence (odds ratio = 0.04; 95% confidence interval: 0.01-0.20; $P < .0001$). The analysis also demonstrated significant heterogeneity between the included studies ($\text{Chi}^2 = 20.70$; $P = .003$; $I^2 = 81\%$).

Conclusion: Repeat resection, SRS, SRT, and XRT play a role in the management of patients with recurrent or residual NFPAs. SRS or some type of radiation therapy is typically performed for patients with residual tumor or tumor recurrence after resection.

Keywords

Nonfunctioning pituitary adenoma, stereotactic radiosurgery, radiation therapy, systematic review, practice guidelines

Abbreviations

NFPA = nonfunctioning pituitary adenoma, SRS = stereotactic radiosurgery, XRT = fractionated radiation therapy.

RECOMMENDATIONS

Question

Should patients with recurrent or residual nonfunctioning pituitary adenomas (NFPAs) undergo stereotactic radiosurgery (SRS), fractionated radiation therapy (eg, XRT, fractionated stereotactic radiotherapy [SRT], or intensity modulated radiotherapy[IMRT]), or repeat resection?

Target Population

These recommendations apply to adult patients with recurrent or residual nonfunctioning pituitary adenomas (NFPAs).

Level II Recommendations

- Radiosurgery and radiation therapy are recommended for treatment of residual or recurrent NFPAs to lower the risk of subsequent tumor progression.
- When no residual tumor is present or only a small intrasellar tumor exists postoperatively, serial neuroimaging studies are recommended.
- Radiosurgery using single-session doses of 12 or more Gy or radiation therapy with fractionated doses of 45 to 54 Gy is recommended for greater local tumor control rate of 90% or higher at 5 years after treatment.

Level III Recommendations

- Assessment of NFPA proliferative index and ACTH staining to identify silent corticotrophic adenomas are recommended for providing guidance regarding the risk of adenoma progression and the benefit of earlier adjuvant radiation.
- Repeat resection is recommended for the treatment of symptomatic recurrent or residual NFPAs.
- Radiosurgery or radiation therapy for NFPAs is recommended when residual/recurrent sellar or parasellar tumor exists and the risk of a repeat resection is high.

INTRODUCTION

Pituitary adenomas are relatively common tumors, and, in fact, they are found in 10%-27% of the general population.^{1,2} Nonfunctioning pituitary adenomas (NFPAs) do not secrete a pituitary hormone, but they may exhibit immunohistochemical positivity for one or more hormones. NFPAs comprise approximately one-third of all pituitary adenomas. Most NFPAs exhibit symptoms as a result of mass effect on adjacent structures such as the optic apparatus, the normal pituitary gland or stalk, or cranial nerves traversing the cavernous sinus. Historically, many NFPAs are diagnosed as macroadenomas. However, in part with the increasing access to neuroimaging modalities such as MRI, nonfunctioning ones can also be found incidentally and diagnosed as microadenomas.

Pituitary adenomas represent challenging clinical entities that neurosurgeons must contend with. Surgical resection, typically through a transsphenoidal corridor, is the upfront treatment for

NFPAs. However, some NFPAs can be difficult to cure with surgery alone. Tumor recurrence or incomplete resection can occur in many pituitary adenoma patients. Nearly a century ago, Harvey Cushing realized the limitations of microsurgical approaches for treating pituitary adenomas. Cushing and his colleagues used a radium bomb to deliver a single-session, focused radiation to treat pituitary adenomas.^{3,4} Henceforth, neurosurgeons and radiation oncologists have employed repeat resection or ionizing radiation to treat selected patients with recurrent or residual pituitary adenomas.

Authors perform a systematic review of the treatment options for residual or recurrent NFPAs. In this review, authors critically evaluate the evidence to support the options of repeat microsurgical resection, stereotactic radiosurgery (SRS), stereotactic radiotherapy (SRT), and fractionated radiation therapy (XRT). In addition, authors provide guidelines for the use of the approaches in the management of recurrent or residual NFPAs. These guidelines are based upon the evidence currently available in the published literature.

METHODOLOGY

Process Overview

The evidence-based clinical practice guideline task force members and the Tumor Section of the American Association of Neurological Surgeons (AANS) and the Congress of Neurological (CNS) conducted a systematic review of the literature relevant to the management of NFPAs. Additional details of the systematic review are provided below and within the introduction and methodology chapter of the guideline.

Disclaimer of Liability

This clinical systematic review and evidence-based guideline was developed by a physician volunteer task force as an educational tool that reflects the current state of knowledge at the time of completion. The presentations are designed to provide an accurate review of the subject matter covered. This guideline is disseminated with the understanding that the recommendations by the authors and consultants who have collaborated in its development are not meant to replace the individualized care and treatment advice from a patient's physician(s). If medical advice or assistance is required, the services of a physician should be sought. The recommendations contained in this guideline may not be suitable for use in all circumstances. The choice to implement any particular recommendation contained in this guideline must be made by a managing physician in light of the situation in each particular patient and on the basis of existing resources.

Potential Conflicts of Interest

All NFPA Guideline Task Force members were required to disclose all potential COIs prior to beginning work on the guideline, using the COI disclosure form of the AANS/CNS Joint Guidelines Committee (JGC). The CNS Guidelines Committee and Guideline Task Force Chair reviewed the disclosures and either approved or disapproved the nomination and participation on the task force. The CNS Guidelines Committee and Guideline Task Force Chair may approve

nominations of task force members with possible conflicts and restrict the writing, reviewing, and/or voting privileges of that person to topics that are unrelated to the possible COIs.

Literature Search

The task force collaborated with a medical librarian to search for articles published from January 1, 1966, to October 1, 2014. Authors searched 2 electronic databases, PubMed and The Cochrane Central Register of Controlled Trials. Strategies for searching electronic databases were constructed by the evidence-based clinical practice guideline taskforce members and the medical librarian, using previously published search strategies to identify relevant studies (Appendix A).⁵⁻¹² The Cochrane Library was searched for all NFPA articles. There were no specific Cochrane reviews for pituitary adenomas. Therefore, all appropriate references were found in the aforementioned PubMed search.

Statistical Analyses of Pooled Data

To compare the tumor control rates between patients who underwent adjuvant radiation therapy and patients who were treated conservatively, the pooled data were analyzed using Review Manager version 5.2.8 (The Nordic Cochrane Centre; The Cochrane Collaboration, 2012). The tumor control rates were extracted for the patients who underwent SRS, SRT, and XRT as adjuvant treatment, and for patients who chose observation. Studies with tumor control rates of NFA comparing adjuvant SRS and observation were included in the meta-analysis. Odds ratios for individual studies and the sum of the included studies were computed using the Mantel-Haenszel test.

Under the assumptions of possible clinical diversity among the included studies, the random effects model was implemented in the analyses for this review. Study heterogeneity was detected using the chi-square and I^2 test statistics. In general, a small number of studies in the analyses lower the power of the chi-square test. Therefore, both a chi-square value within the 10% ($P < .10$) and a I^2 value exceeding 50% were required for significance.

RESULTS AND DISCUSSION

The search resulted in 95 articles, and 46 were excluded based on the inclusion and exclusion criteria mentioned above according to the title and abstract. The remaining 49 articles were included, and these were as follows: outcome of repeat surgical resection ($n = 4$), outcome of radiosurgery (ie, single-session or hypofractionated stereotactic radiosurgery [SRS]) ($n = 24$), or fractionated radiotherapy (ie, stereotactic radiotherapy [SRT], conventional fractionated radiotherapy [XRT]) ($n = 21$) (Figure 1). This review highlights the most important contributions on the treatment efficacy in residual/recurrent NFPA of surgical approaches, on radiosurgery, and on studies aimed at the identification of new markers in relation to tumor behavior or response to treatment.

Repeat Resection

Although a few studies have assessed the long-term results of surgery alone as a definitive treatment for NFPAs, the recurrence after initial resection has been noted to be as high as 44%-

75% within a 10-year period of time after resection.¹³⁻¹⁶ Those with cavernous sinus invasion, larger tumor remnant, and extrasellar location (ie, cavernous sinus invasion) were more likely to exhibit tumor regrowth. Factors portending a more favorable chance of tumor control were those with a smaller tumor remnant and older age.¹⁷⁻²⁰ Therefore, for the residual NFAs that were tending to grow, the adjuvant treatment was suggested, either repeated surgery SRS or radiation therapy.

Four studies of repeat resection met inclusion for this guidelines project (Table 1). Of these studies, all represented retrospective, class III evidence.²¹⁻²⁴ In a study by Cappabianca et al,²¹ repeat resection was carried out with an endoscopic, transsphenoidal approach. Gross total resection was achieved in 2 of 6 patients; no hypopituitarism or other complications were noted. In another larger study, Cavallo et al²² performed repeat endoscopic resection via a transsphenoidal approach, and they achieved gross total resection of 62%. Prior microsurgical resection portended a greater chance of gross total resection, whereas prior endoscopic resection was related to a lower rate of gross total resection. In the largest of the studies by Chang et al,²³ visual deterioration was seen in 5%, permanent diabetes insipidus in 1.2%, transient diabetes insipidus in 4.9%, meningitis in 2.5%, postoperative hematoma in 2.5%, and perioperative mortality in 1.2%.

Thus, repeat resection for an NFPA would seem reasonable for those with larger, symptomatic residual or recurrent tumors (ie, optic compressive neuropathy, other cranial nerve dysfunction, or hydrocephalus). The use of specific surgical approaches depends on the location of a residual/recurrent tumor. A lesion invading the cavernous sinus, suprasellar region, or even the hypothalamus is usually more difficult to treat via surgical resection, although some neurosurgeons have great experience in pterional, subfrontal, or interhemispherical approaches. There is insufficient evidence in the literature to recommend one particular surgical technique (ie, endoscopic versus microscopic) for those requiring repeat resection. While most recent publications are focused on comparing the conventional microsurgical approach to the endoscopic approach, the evidence does not show that the endoscopic TSS approach for residual/recurrent NFPA is superior to the microscopic TSS approach in terms of the rate of gross total resection or the endocrinological outcome, although the endoscopic approach did reduce hospital stay (class III evidence), perioperative morbidity (lumbar drains or labial complications), and patient discomfort as compared to the microscopic approach. However, there is one report that suggests that the application of a different approach than the one used in the initial resection may be helpful for gross total resection of residual/recurrent NFPA.²² Similarly, a few studies demonstrated some advanced surgical techniques such as intraoperative optic nerve identification, intraoperative MRI,²⁵⁻²⁷ or with pituitary transposition to reduce the rate of incomplete resection.²⁸

Although there is no direct comparison, second transsphenoidal approaches appear to convey higher complication rates, varying from 1%-22%.^{17, 21-24} The complications include hypopituitarism (<5%), cerebrospinal fluid (CSF) leakage (1.5%-2.5%), postoperative hyponatremia (3.7%), transient or permanent diabetes insipidus (<5%), visual deterioration (<5%), meningitis (2.5%), hematoma on the tumor bed (1.7%), epistaxis, sinusitis, and anesthetic risks. Incomplete resection or failure to identify the remaining adenoma secondary to obscured anatomy can also occur during repeat resection.

Stereotactic Radiosurgery for Residual/Recurrent Nonfunctioning Pituitary Adenomas

In 1951, Lars Leksell, a neurosurgeon, devised the concept of SRS. He described SRS as the “closed skull destruction of an intracranial target using ionizing radiation.”²⁹ Seventeen years later, Leksell treated the first pituitary adenoma patient using the Gamma Knife.

SRS delivers a precisely focused and high dose of ionizing radiation to the target while sparing surrounding structures of appreciable radiation. Radiosurgery is usually delivered in a single session, but it may be delivered in up to 5 sessions (ie, fractions) in recent SRS models.³⁰ For cobalt-based SRS devices such as the Gamma Knife, the steepest gradient index is achieved around the 50% isodose line, whereas for linear accelerators (LINACs)-based radiosurgical systems, it is usually achieved at an 80% to 90% isodose line. As such, a radiosurgical dose plan with the Gamma Knife will have more heterogeneity within the target volume than a LINAC-based treatment. A margin dose of 12 to 20 Gy is frequently used for single-session radiosurgery of NFPAs.

For treating NFPAs, careful attention to the neuro-anatomy is important, and this holds true for both radiosurgery and fractionated radiation therapy. Accurate contouring of the target and adjacent critical structures is required. In order to develop an accurate dose plan, a patient undergoes at least one type of stereotactic neuroimaging. For pituitary adenoma patients, this is most frequently a stereotactic MRI and/or CT. During radiosurgical delivery, semi-rigid or rigid target immobilization of the patient’s cranium is utilized. Patients are immobilized using rigid frames fixed to the skull or other immobilization such as thermoplastic masks or bite blocks. Each immobilization device has a stereotactic coordinate system. Radiosurgery is image guided, and it reliably confers sub-millimeter accuracy for intracranial targets. With the use of onboard imaging systems (eg, cone beam CT or orthogonal X-rays) or patient movement detection systems (eg, systems with vacuum detection for patient motion or infrared tracking), patient tracking and compensation for errors (eg, set-up error, patient movement, etc) can be made. The literature review revealed the routine use of commercially available radiosurgical delivery devices including the Gamma Knife (Elekta AB, Crawley, United Kingdom), modified linear accelerators (LINACs) such as Novalis (Brainlab, Munich, Germany) and Cyberknife (Accuray, Sunnyvale, California), and proton beam units.

Regarding outcome of SRS for recurrent or residual NFAs, we identified 24 studies that met the predefined study criteria. Of these, 2 studies were Class II evidence,^{31,32} whereas the remaining represented Class III evidence (Table 2).³³⁻⁵⁴

Overall, tumor control of NFPAs with SRS varied from 83% to 100% (Table 2). In a case-controlled (ie, Class II) study by Picozzi et al,³¹ 5-year progression-free survival in radiosurgically managed NFA patients was 89.8% compared to 51.1% in untreated NFA patients. In the largest study to date, Sheehan et al³³ demonstrated progression-free survival at 3, 5, 8, and 10 years of 98%, 95%, 91%, and 85%, respectively. Those with a smaller adenoma volume were more likely to exhibit post-SRS tumor control, whereas those with suprasellar extension were less likely to do so. Other studies, including those from Park et al,³⁶ Starke et al,³⁴ and Gopalan et al,³⁸ demonstrate the diminished effectiveness of radiosurgical tumor control for larger-volume adenomas. In addition, lower radiosurgical margin dose, particularly below 12 Gy, appears to confer a lower rate of long-term tumor control.^{44,45,50} While most of the radiosurgical literature

was composed of Gamma Knife-based series, several linear accelerator-based radiosurgical series afforded a high rate of NFA control.^{35,37}

For complication after SRS, hypopituitarism is the most frequently occurring unintended side effect of radiosurgery for an NFA. Rates of hypopituitarism ranged from 0% to 39% in the identified series (Table 2). The second most common side effect from radiosurgery is a cranial neuropathy. Optic nerve dysfunction varied from 0% to 12.8%. Other deficits involving cranial nerves III, IV, and VI varied from 0% to 13.7% (Table 2). In the identified studies, no cases of radiation-induced neoplasia or cerebral ischemia were noted from SRS of an NFPA.

Fractionated Radiation Therapy for Residual/Recurrent Nonfunctioning Pituitary Adenomas

Conventional fractionated radiation therapy includes various types, such as conventional fractionated radiotherapy (XRT), charged particle (most frequently proton [PBRT] or carbon ion) radiotherapy, intensity modulated radiotherapy (IMRT), and stereotactic radiotherapy (SRT). Radiotherapy has been utilized for decades to treat patients with NFPA. Four-field techniques for the skull base used anterior-posterior and lateral opposing fields. The technique of radiation therapy has undergone substantial technological leaps over the past decade. As such, a four-field approach has been supplanted by techniques such as 3-dimensional conformal radiation therapy and intensity-modulated therapy. During radiation therapy, the patient's head is usually immobilized in a tight-fitting mask. Common fractionated doses to pituitary adenomas are 45 to 54 Gy at 1.8 to 2 Gy per fraction per day. Four to 5 fractions are delivered per week over the time span of 5 to 6 weeks.

Utilizing the aforementioned search criteria, we identified 20 XRT/SRT studies that met inclusion criteria (Table 3). Of these studies, 4 studies represent Class II evidence,⁵⁵⁻⁵⁸ while the remaining studies represent Class III evidence.^{37,59-74}

In the studies, tumor control following XRT or SRT varied from 74% to 100% (Table 3). In one large and long-term study comprising 120 patients with a mean follow-up of 108 months, progression-free survival was noted to be 87.5%, 77.6%, and 64.7% at 10, 20, and 30 years after XRT, respectively.⁶⁸ In a study by Woollons et al,⁵⁸ in 72 patients with a mean follow-up of 64 months and representing Class II evidence, radiation therapy resulted in tumor control in 74% of patients as compared to 54% in pituitary adenoma patients not treated with XRT. In another study by Park et al,⁵⁷ early XRT resulted in an improvement in tumor control as compared to observation alone.

For the complications after XRT and SRT, immediate side effects may include nausea and some fatigue. These symptoms are usually mild, but they may last 1 to 2 months after radiation treatment. Hair loss at the entry sites, decreased taste, and diminished olfaction can also occur after XRT and SRT. Similar to SRS, the most common side effect after XRT and SRT is radiation-induced hypopituitarism. Hypopituitarism in the studies that met inclusion criteria ranged from 0% to 88% (Table 3). Using conventional dose and fractionation schemes, the rate of radiation-induced damage to the visual pathways with XRT is 1% to 5% (Table 3). Rare instances of radiation-induced tumor formation (eg, parasellar fibrosarcomas), cerebral ischemia from carotid stenosis, and neuropsychological or cognitive changes have also been described. The risk of cognitive changes is an important area for future investigation, ideally comparing XRT to SRS, as

outlined at the end of this manuscript. Cerebrovascular complications following radiation therapy were noted to be 4.5% in the series by Langsenlehner et al.⁶¹ In Breen's series of 120 patients previously noted, radiation-induced neoplasia occurred in 1.7% of patients.⁶⁸

Comparing Repeat Resection, Stereotactic Radiosurgery, and Radiation Therapy

There is no Class I comparison of repeat resection, XRT, and SRS for recurrent/residual NFPAs. Resection is typically utilized in those with larger adenomas for whom relief of mass effect is desired. Patient preference and fitness for a repeat surgery will also naturally impact the decision to proceed with a repeat resection.

Meta-analysis from 5 Class II studies with recurrence rates for both adjuvant radiation therapy and observation demonstrated that fractionated radiation therapy for residual/recurrent NFA offered a lower rate of recurrence (OR = 0.04; 95% CI: 0.01-0.20; $P < .0001$). The analysis also demonstrated significant heterogeneity between the included studies ($\text{Chi}^2 = 20.70$; $P = .003$; $I^2 = 81\%$). The result of the meta-analysis was demonstrated in Figure 2.

In terms of specific radiation treatment modalities, clinicians must select the approach (SRS, IMRT, PBRT, SRT, or XRT) that permits a highly targeted irradiation of the NFPA while still achieving a dose considered tolerable to adjacent critical structures based upon radiotoxicity guidelines such as the Quantitative Analyses of Normal Tissue Effects in the Clinic (QUANTEC) studies.⁷⁵

CONCLUSION

For patients with residual or recurrent NFPA, long-term tumor control can be achieved with radiation, with modalities including SRS, SRT, IMRT, PBRT, or XRT. For those with a known residual adenoma, radiographic signs of progression make for a more compelling reason to intercede and retreat the adenoma. Radiographic signs of progression in the setting of younger patients or patients with symptoms attributable to progression should be considered even more strongly for intervention.

Delayed hypopituitarism is the most common complication after SRS, SRT, IMRT, PBRT, or XRT. Other serious complications after SRS, SRT, IMRT, PBRT, and XRT are rare. Patients with residual or recurrent NFPAs undergoing repeat resection, SRS, SRT, IMRT, PBRT, or XRT should have long-term follow-up.

Future Research

- The timing of SRS or XRT after prior resection warrants further investigation.
- While radiosurgery and radiation therapy are seldom used as an upfront treatment for patients with NFPAs, there are favorable but limited reports of initial SRS as a management for NFPAs. Further evaluation of this treatment approach is warranted.
- Similarly, the role of multisession (ie, hypofractionated) radiosurgery for NFPAs, particularly those exhibiting larger volumes or in close proximity to critical structures, has

been explored in limited publications. Optimal dose and fractionation schemes, particularly for SRS of NFPAs, should be explored.

- The neurocognitive effects of SRS and XRT in pituitary adenoma patients warrants further study with the use of validated neurocognitive tests and appropriate assessment intervals.

Disclosure of Funding

These evidence-based clinical practice guidelines were funded exclusively by the CNS and the Tumor Section of the CNS and the AANS, which received no funding from outside commercial sources to support the development of this document.

Acknowledgments

The authors acknowledge the CNS Guidelines Committee for their contributions throughout the development of the guideline, the AANS/CNS Joint Guidelines Committee for their review, comments, and suggestions throughout peer review, and Pamela Shaw, MSLIS, MS, for assistance with the literature searches. Also, the authors acknowledge the following individual peer reviewers for their contributions: Sepideh Amin-Hanjani, MD, Kathryn Holloway, MD, Odette Harris, MD, Brad Zacharia, MD, Daniel Hoh, MD, Isabelle Germano, MD, Martina Stippler, MD, Kimon Bekelis, MD, Christopher Winfree, MD and William Mack, MD. Lastly, and most significantly, the authors would like to acknowledge Edward Laws, MD, for serving as an advisor on this nonfunctioning adenoma guidelines project and providing comprehensive critical appraisal.

Disclosure

The authors have no personal, financial, or institutional interest in any of the drugs, materials, or devices described in this article.

REFERENCES

1. Dekkers OM, Pereira AM, Romijn JA. Treatment and follow-up of clinically nonfunctioning pituitary macroadenomas. *J Clin Endocrinol Metab.* 2008;93(10):3717-3726.
2. Vance ML. Treatment of patients with a pituitary adenoma: one clinician's experience. *Neurosurg Focus.* 2004;16(4):E1.
3. Schulder M, Loeffler JS, Howes AE, Alexander E, 3rd, Black PM. Historical vignette: The radium bomb: Harvey Cushing and the interstitial irradiation of gliomas. *J Neurosurg.* 1996;84(3):530-532.
4. Seymour ZA, Cohen-Gadol AA. Cushing's lost cases of "radium bomb" brachytherapy for gliomas. *J Neurosurg.* 2010;113(1):141-148.
5. Kastner M, Wilczynski NL, Walker-Dilks C, McKibbin KA, Haynes B. Age-specific search strategies for Medline. *J. Med. Internet Res.* 2006;8(4):e25.
6. Haynes RB, McKibbin KA, Wilczynski NL, Walter SD, Werre SR, Hedges T. Optimal search strategies for retrieving scientifically strong studies of treatment from Medline: analytical survey. *BMJ.* 2005;330(7501):1179.
7. Montori VM, Wilczynski NL, Morgan D, Haynes RB, Hedges T. Optimal search strategies for retrieving systematic reviews from Medline: analytical survey. *BMJ.* 2005;330(7482):68.
8. Wong SS, Wilczynski NL, Haynes RB. Comparison of top-performing search strategies for detecting clinically sound treatment studies and systematic reviews in MEDLINE and EMBASE. *Journal of the Medical Library Association : JMLA.* 2006;94(4):451-455.
9. Zhang L, Ajiferuke I, Sampson M. Optimizing search strategies to identify randomized controlled trials in MEDLINE. *BMC Med. Res. Methodol.* 2006;6:23.
10. Topfer LA, Parada A, Menon D, Noorani H, Perras C, Serra-Prat M. Comparison of literature searches on quality and costs for health technology assessment using the MEDLINE and EMBASE databases. *Int. J. Technol. Assess. Health Care.* 1999;15(2):297-303.
11. Wilczynski NL, Haynes RB. Developing optimal search strategies for detecting clinically sound prognostic studies in MEDLINE: an analytic survey. *BMC Med.* 2004;2:23.
12. Wilczynski NL, Haynes RB, Hedges T. EMBASE search strategies achieved high sensitivity and specificity for retrieving methodologically sound systematic reviews. *J. Clin. Epidemiol.* 2007;60(1):29-33.
13. Boelaert K, Gittoes NJ. Radiotherapy for non-functioning pituitary adenomas. *Eur J Endocrinol.* 2001;144(6):569-575.
14. Comtois R, Beauregard H, Somma M, Serri O, Aris-Jilwan N, Hardy J. The clinical and endocrine outcome to trans-sphenoidal microsurgery of nonsecreting pituitary adenomas. *Cancer.* 1991;68(4):860-866.

15. Greenman Y, Ouaknine G, Veshchev I, Reider G, II, Segev Y, Stern N. Postoperative surveillance of clinically nonfunctioning pituitary macroadenomas: markers of tumour quiescence and regrowth. *Clin Endocrinol (Oxf)*. 2003;58(6):763-769.
16. Turner HE, Stratton IM, Byrne JV, Adams CB, Wass JA. Audit of selected patients with nonfunctioning pituitary adenomas treated without irradiation - a follow-up study. *Clin Endocrinol (Oxf)*. 1999;51(3):281-284.
17. Benveniste RJ, King WA, Walsh J, Lee JS, Delman BN, Post KD. Repeated transsphenoidal surgery to treat recurrent or residual pituitary adenoma. *J Neurosurg*. 2005;102(6):1004-1012.
18. Berkmann S, Schlaffer S, Buchfelder M. Tumor shrinkage after transsphenoidal surgery for nonfunctioning pituitary adenoma. *J Neurosurg*. 2013;119(6):1447-1452.
19. O'Sullivan EP, Woods C, Glynn N, et al. The natural history of surgically treated but radiotherapy-naïve nonfunctioning pituitary adenomas. *Clin Endocrinol (Oxf)*. 2009;71(5):709-714.
20. Tanaka Y, Hongo K, Tada T, Sakai K, Kakizawa Y, Kobayashi S. Growth pattern and rate in residual nonfunctioning pituitary adenomas: correlations among tumor volume doubling time, patient age, and MIB-1 index. *J Neurosurg*. 2003;98(2):359-365.
21. Cappabianca P, Alfieri A, Colao A, et al. Endoscopic endonasal transsphenoidal surgery in recurrent and residual pituitary adenomas: technical note. *Minim Invasive Neurosurg*. 2000;43(1):38-43.
22. Cavallo LM, Solari D, Tasiou A, et al. Endoscopic endonasal transsphenoidal removal of recurrent and regrowing pituitary adenomas: experience on a 59-patient series. *World Neurosurg*. 2013;80(3-4):342-350.
23. Chang EF, Sughrue ME, Zada G, Wilson CB, Blevins LS, Jr., Kunwar S. Long term outcome following repeat transsphenoidal surgery for recurrent endocrine-inactive pituitary adenomas. *Pituitary*. 2010;13(3):223-229.
24. Rudnik A, Zawadzki T, Galuszka-Ignasiak B, et al. Endoscopic transsphenoidal treatment in recurrent and residual pituitary adenomas--first experience. *Minim Invasive Neurosurg*. 2006;49(1):10-14.
25. Coburger J, Konig R, Seitz K, Bazner U, Wirtz CR, Hlavac M. Determining the utility of intraoperative magnetic resonance imaging for transsphenoidal surgery: a retrospective study. *J Neurosurg*. 2013;120(2):346-356.
26. Paterno V, Fahlbusch R. High-Field iMRI in transsphenoidal pituitary adenoma surgery with special respect to typical localization of residual tumor. *Acta Neurochir (Wien)*. 2014;156(3):463-474.
27. Tanei T, Nagatani T, Nakahara N, et al. Use of high-field intraoperative magnetic resonance imaging during endoscopic transsphenoidal surgery for functioning pituitary microadenomas and small adenomas located in the intrasellar region. *Neurol Med Chir (Tokyo)*. 2013;53(7):501-510.

28. Taussky P, Kalra R, Coppens J, Mohebali J, Jensen R, Couldwell WT. Endocrinological outcome after pituitary transposition (hypophysopexy) and adjuvant radiotherapy for tumors involving the cavernous sinus. *J Neurosurg.* 2011;115(1):55-62.
29. Leksell L. The stereotaxic method and radiosurgery of the brain. *Acta Chir Scand.* Dec 13 1951;102(4):316-319.
30. Barnett GH, Linskey ME, Adler JR, et al. Stereotactic radiosurgery--an organized neurosurgery-sanctioned definition. *J Neurosurg.* 2007;106(1):1-5.
31. Picozzi P, Losa M, Mortini P, et al. Radiosurgery and the prevention of regrowth of incompletely removed nonfunctioning pituitary adenomas. *J Neurosurg.* 2005;102 Suppl:71-74.
32. Wilson PJ, De-Loyde KJ, Williams JR, Smee RI. A single centre's experience of stereotactic radiosurgery and radiotherapy for non-functioning pituitary adenomas with the Linear Accelerator (Linac). *J Clin Neurosci.* 2012;19(3):370-374.
33. Sheehan JP, Starke RM, Mathieu D, et al. Gamma Knife radiosurgery for the management of nonfunctioning pituitary adenomas: a multicenter study. *J Neurosurg.* 2013;119(2):446-456.
34. Starke RM, Williams BJ, Jane JA, Jr., Sheehan JP. Gamma Knife surgery for patients with nonfunctioning pituitary macroadenomas: predictors of tumor control, neurological deficits, and hypopituitarism. *J Neurosurg.* 2012;117(1):129-135.
35. Runge MJ, Maarouf M, Hunsche S, et al. LINAC-radiosurgery for nonsecreting pituitary adenomas. Long-term results. *Strahlenther Onkol.* 2012;188(4):319-325.
36. Park KJ, Kano H, Parry PV, et al. Long-term outcomes after gamma knife stereotactic radiosurgery for nonfunctional pituitary adenomas. *Neurosurgery.* 2011;69(6):1188-1199.
37. Iwata H, Sato K, Tatewaki K, et al. Hypofractionated stereotactic radiotherapy with CyberKnife for nonfunctioning pituitary adenoma: high local control with low toxicity. *Neuro Oncol.* 2011;13(8):916-922.
38. Gopalan R, Schlesinger D, Vance ML, Laws E, Sheehan J. Long-term outcomes after Gamma Knife radiosurgery for patients with a nonfunctioning pituitary adenoma. *Neurosurgery.* 2011;69(2):284-293.
39. Hayashi M, Chernov M, Tamura N, et al. Gamma Knife robotic microradiosurgery of pituitary adenomas invading the cavernous sinus: treatment concept and results in 89 cases. *J Neurooncol.* 2010;98(2):185-194.
40. Hoybye C, Rahn T. Adjuvant Gamma Knife radiosurgery in non-functioning pituitary adenomas; low risk of long-term complications in selected patients. *Pituitary.* 2009;12(3):211-216.
41. Pollock BE, Cochran J, Natt N, et al. Gamma knife radiosurgery for patients with nonfunctioning pituitary adenomas: results from a 15-year experience. *Int J Radiat Oncol Biol Phys.* 2008;70(5):1325-1329.

42. Jagannathan J, Sheehan JP, Pouratian N, Laws ER, Jr., Steiner L, Vance ML. Gamma knife radiosurgery for acromegaly: outcomes after failed transsphenoidal surgery. *Neurosurgery*. 2008;62(6):1262-1269; discussion 1269-1270.
43. Liscak R, Vladyka V, Marek J, Simonova G, Vymazal J. Gamma knife radiosurgery for endocrine-inactive pituitary adenomas. *Acta Neurochir (Wien)*. 2007;149(10):999-1006; discussion 1006.
44. Mingione V, Yen CP, Vance ML, et al. Gamma surgery in the treatment of nonsecretory pituitary macroadenoma. *J Neurosurg*. 2006;104(6):876-883.
45. Muacevic A, Uhl E, Wowra B. Gamma knife radiosurgery for nonfunctioning pituitary adenomas. *Acta Neurochir Suppl*. 2004;91:51-54.
46. Losa M, Valle M, Mortini P, et al. Gamma knife surgery for treatment of residual nonfunctioning pituitary adenomas after surgical debulking. *J Neurosurg*. 2004;100(3):438-444.
47. Kuo JS, Chen JC, Yu C, et al. Gamma knife radiosurgery for benign cavernous sinus tumors: quantitative analysis of treatment outcomes. *Neurosurgery*. 2004;54(6):1385-1393; discussion 1393-1384.
48. Pollock BE, Carpenter PC. Stereotactic radiosurgery as an alternative to fractionated radiotherapy for patients with recurrent or residual nonfunctioning pituitary adenomas. *Neurosurgery*. 2003;53(5):1086-1091; discussion 1091-1084.
49. Petrovich Z, Yu C, Giannotta SL, Zee CS, Apuzzo ML. Gamma knife radiosurgery for pituitary adenoma: early results. *Neurosurgery*. 2003;53(1):51-59; discussion 59-61.
50. Wowra B, Stummer W. Efficacy of gamma knife radiosurgery for nonfunctioning pituitary adenomas: a quantitative follow up with magnetic resonance imaging-based volumetric analysis. *J Neurosurg*. 2002;97(5 Suppl):429-432.
51. Sheehan JP, Kondziolka D, Flickinger J, Lunsford LD. Radiosurgery for residual or recurrent nonfunctioning pituitary adenoma. *J Neurosurg*. 2002;97(5 Suppl):408-414.
52. Feigl GC, Bonelli CM, Berghold A, Mokry M. Effects of gamma knife radiosurgery of pituitary adenomas on pituitary function. *J Neurosurg*. 2002;97(5 Suppl):415-421.
53. Mokry M, Ramschak-Schwarzer S, Simbrunner J, Ganz JC, Pendl G. A six year experience with the postoperative radiosurgical management of pituitary adenomas. *Stereotact Funct Neurosurg*. 1999;72 Suppl 1:88-100.
54. Lim YL, Leem W, Kim TS, Rhee BA, Kim GK. Four years' experiences in the treatment of pituitary adenomas with gamma knife radiosurgery. *Stereotact Funct Neurosurg*. 1998;70 Suppl 1:95-109.
55. Losa M, Mortini P, Barzagli R, et al. Early results of surgery in patients with nonfunctioning pituitary adenoma and analysis of the risk of tumor recurrence. *J Neurosurg*. 2008;108(3):525-532.
56. van den Bergh AC, van den Berg G, Schoorl MA, et al. Immediate postoperative radiotherapy in residual nonfunctioning pituitary adenoma: beneficial effect on local

- control without additional negative impact on pituitary function and life expectancy. *Int J Radiat Oncol Biol Phys*. 2007;67(3):863-869.
57. Park P, Chandler WF, Barkan AL, et al. The role of radiation therapy after surgical resection of nonfunctional pituitary macroadenomas. *Neurosurgery*. 2004;55(1):100-106; discussion 106-107.
 58. Woollons AC, Hunn MK, Rajapakse YR, et al. Non-functioning pituitary adenomas: indications for postoperative radiotherapy. *Clin Endocrinol (Oxf)*. 2000;53(6):713-717.
 59. Kopp C, Theodorou M, Poullos N, et al. Fractionated stereotactic radiotherapy in the treatment of pituitary adenomas. *Strahlenther Onkol*. 2013;189(11):932-937.
 60. Chang EF, Zada G, Kim S, et al. Long-term recurrence and mortality after surgery and adjuvant radiotherapy for nonfunctional pituitary adenomas. *J Neurosurg*. 2008;108(4):736-745.
 61. Langsenlehner T, Stiegler C, Quehenberger F, et al. Long-term follow-up of patients with pituitary macroadenomas after postoperative radiation therapy: analysis of tumor control and functional outcome. *Strahlenther Onkol*. 2007;183(5):241-247.
 62. Selch MT, Gorgulho A, Lee SP, et al. Stereotactic radiotherapy for the treatment of pituitary adenomas. *Minim Invasive Neurosurg*. 2006;49(3):150-155.
 63. Minniti G, Traish D, Ashley S, Gonsalves A, Brada M. Fractionated stereotactic conformal radiotherapy for secreting and nonsecreting pituitary adenomas. *Clin Endocrinol (Oxf)*. 2006;64(5):542-548.
 64. Paek SH, Downes MB, Bednarz G, et al. Integration of surgery with fractionated stereotactic radiotherapy for treatment of nonfunctioning pituitary macroadenomas. *Int J Radiat Oncol Biol Phys*. 2005;61(3):795-808.
 65. Kokubo M, Sasai K, Shibamoto Y, et al. Long-term results of radiation therapy for pituitary adenoma. *J Neurooncol*. 2000;47(1):79-84.
 66. Jalali R, Brada M, Perks JR, et al. Stereotactic conformal radiotherapy for pituitary adenomas: technique and preliminary experience. *Clin Endocrinol (Oxf)*. 2000;52(6):695-702.
 67. Gittoes NJ, Bates AS, Tse W, et al. Radiotherapy for non-function pituitary tumours. *Clin Endocrinol (Oxf)*. 1998;48(3):331-337.
 68. Breen P, Flickinger JC, Kondziolka D, Martinez AJ. Radiotherapy for nonfunctional pituitary adenoma: analysis of long-term tumor control. *J Neurosurg*. 1998;89(6):933-938.
 69. Coke C, Andrews DW, Corn BW, et al. Multiple fractionated stereotactic radiotherapy of residual pituitary macroadenomas: initial experience. *Stereotact Funct Neurosurg*. 1997;69(1-4 Pt 2):183-190.
 70. Zierhut D, Flentje M, Adolph J, Erdmann J, Raue F, Wannemacher M. External radiotherapy of pituitary adenomas. *Int J Radiat Oncol Biol Phys*. 1995;33(2):307-314.

71. Tsang RW, Brierley JD, Panzarella T, Gospodarowicz MK, Sutcliffe SB, Simpson WJ. Radiation therapy for pituitary adenoma: treatment outcome and prognostic factors. *Int J Radiat Oncol Biol Phys.* 1994;30(3):557-565.
72. Brada M, Rajan B, Traish D, et al. The long-term efficacy of conservative surgery and radiotherapy in the control of pituitary adenomas. *Clin Endocrinol (Oxf).* 1993;38(6):571-578.
73. McCollough WM, Marcus RB, Jr., Rhoton AL, Jr., Ballinger WE, Million RR. Long-term follow-up of radiotherapy for pituitary adenoma: the absence of late recurrence after greater than or equal to 4500 cGy. *Int J Radiat Oncol Biol Phys.* 1991;21(3):607-614.
74. Grigsby PW, Simpson JR, Emami BN, Fineberg BB, Schwartz HG. Prognostic factors and results of surgery and postoperative irradiation in the management of pituitary adenomas. *Int J Radiat Oncol Biol Phys.* 1989;16(6):1411-1417.
75. Mayo C, Martel MK, Marks LB, Flickinger J, Nam J, Kirkpatrick J. Radiation dose-volume effects of optic nerves and chiasm. *Int J Radiat Oncol Biol Phys.* 2010;76(3 Suppl):S28-35.

FIGURES

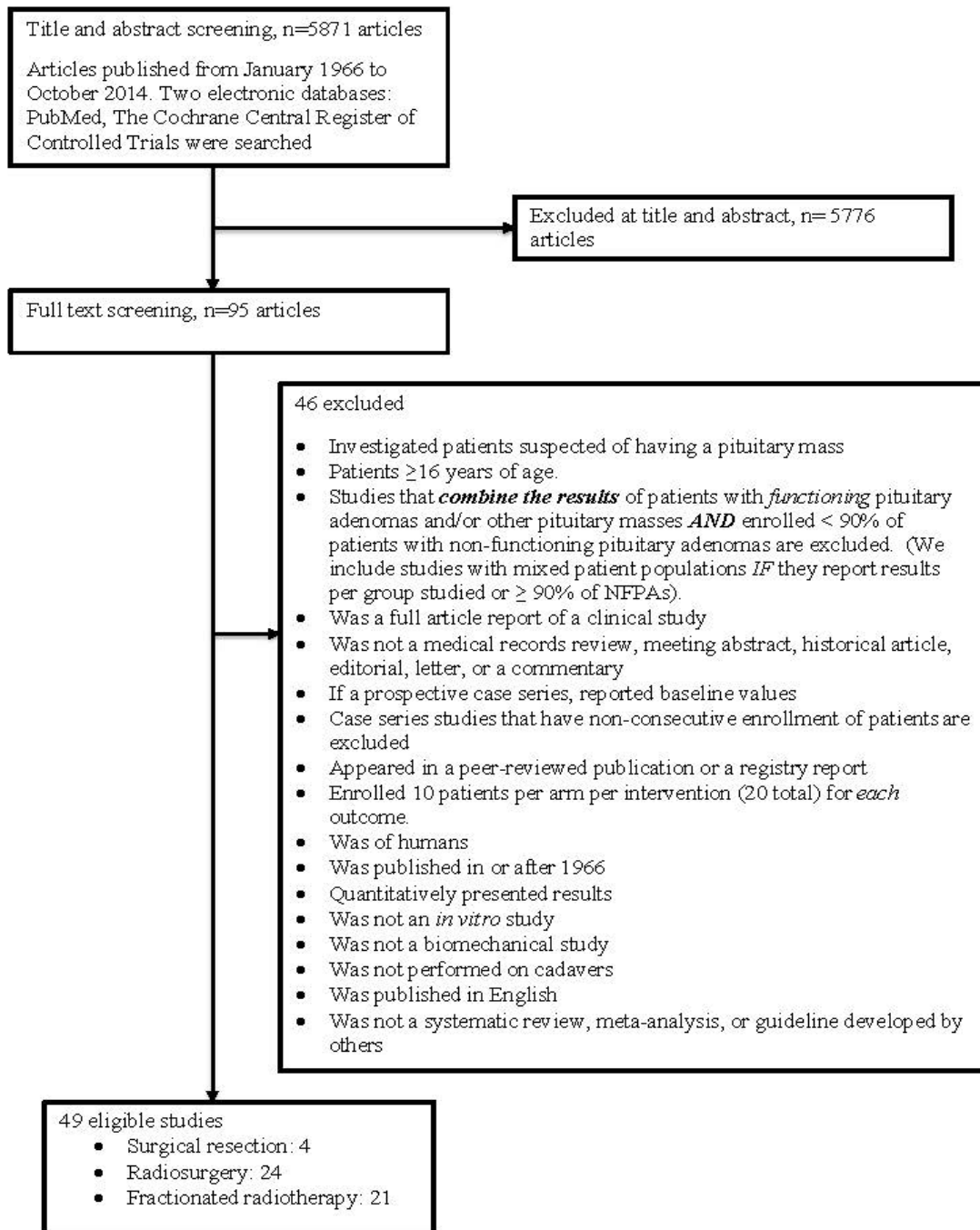


Figure 1 Flow Diagram of Search Process for Identifying Final Number of Eligible Studies

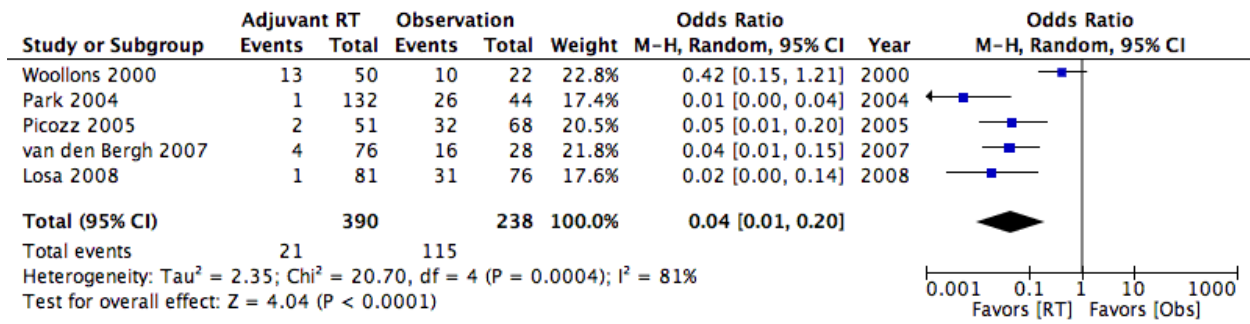


Figure 2 Class II Radiation Therapy Studies and Odds Ratio Favoring Tumor Control with Intervention

TABLES

Table 1: Evidence Detailing Repeated Surgical Resection of a Residual/Recurrent NFPA

Author, year	Study Design / Class / Classification Process	Intervention	Gross total resection rate	Favorable factor	Unfavorable factor	Hypopituitarism	Other complications
Cavallo ²² , 2013	Retrospective / III / Therapeutic	Endoscopic TSS for 59 pts	62%	Prior microsurgical TSS	Prior endoscopic TSS	5%	CSF leakage and meningitis: 1.7% Hematoma on tumor bed: 1.7%
Chang ²³ , 2010	Retrospective / III / Therapeutic	TSS for 81 pts	40%	-	Suprasellar extension and cavernous sinus invasion	-	Visual deterioration: 5%, DI: 4.9%, permanent DI: 1.2%, hyponatremia: 3.7%, sinusitis: 6.2%, spinal headache, 6.2%, meningitis: 2.5%, hematoma: 2.5%, death: 1.2%, overall: 22%
Rudnik ²⁴ , 2006	Retrospective / III / Therapeutic	Endoscopic TSS for 14 pts	43%	-	-	<3%	Epistaxis, DI, sinusitis, CSF rhinorrhea, fat graft harvest site infection, transient cranial nerve palsy
Cappabianca ²¹ , 2000	Retrospective / III / Therapeutic	Endoscopic TSS for 6 pts	33%	-	-	0%	No complications

Table 2: Class III Evidence Detailing Radiosurgery for a Residual/Recurrent NFPA

Author, year	Study Design / Class / Classification Process	Intervention	Follow-up (months)	Tumor control rate	Progressive-free survival (%)	Favorable factor	Unfavorable factor	Hypopituitarism	Other complications
Sheehan ³³ , 2013	Retrospective / III / Therapeutic	GKS for 512	36	93.4%	98%, 95%, 91%, and 85% at 3, 5, 8, and 10 yrs	Smaller adenoma volume	Suprasellar extension	21%	New cranial nerve deficits: 9% New onset optic nerve dysfunction: 6.6%
Wilson ³² , 2012	Case control study / II / Therapeutic	G1: SRS for 51 G2: FSRT for 67 G3: CRT for 53	-	-	At 5 yrs G1:100% G2: 93%, G3: 87%	-	-	-	-
Runge ³⁵ , 2012	Retrospective / III / Therapeutic	LINAC-RS for 61	83	98%	-	-	-	9.8%	New onset optic nerve dysfunction: 0%
Starke ³⁴ , 2012	Retrospective / III / Therapeutic	GKS for 140	60	90%	98%, 97%, 91%, and 87% at 2, 5, 8, and 10 yrs	-	Tumor volume >5 cm ³	30.3%	New cranial nerve deficits: 13.7%, new onset optic nerve dysfunction: 12.8%
Gopalan ³⁸ , 2011	Retrospective / III / Therapeutic	GKS for 48	80.5	83%	-	-	Tumor volume >5 cm ³	39%	New onset optic nerve dysfunction: 9.4%
Iwata ³⁷ , 2011	Retrospective / III / Therapeutic	Hypofractionated SRT for 94	33	-	98%	-	-	4.1%	New onset optic nerve dysfunction: 1%

Author, year	Study Design / Class / Classification Process	Intervention	Follow-up (months)	Tumor control rate	Progressive-free survival (%)	Favorable factor	Unfavorable factor	Hypopituitarism	Other complications
Park ³⁶ , 2011	Retrospective / III / Therapeutic	GKS for 125	62	89.6%	99%, 94%, and 76% at 1, 5, 10 yrs		Tumor volume ≥ 4.5 cm ³ , and ≥ 2 prior recurrences	24%	New cranial nerve deficits: 1.6%, new onset optic nerve dysfunction: 0.8%
Hayashi ³⁹ , 2010	Retrospective / III / Therapeutic	GKS for 43	36	97%	-	-	-	0%	Transient new cranial nerve deficits: 2%
Hoybye ⁴⁰ , 2009	Retrospective / III / Therapeutic	GKS for 23	78	95.7%	-	-	-	0%	-
Jagannathan ⁴² , 2008	Retrospective / III / Therapeutic	GKS for 82	44.9	92%	-	-	-	-	-
Pollock ⁴¹ , 2008	Retrospective / III / Therapeutic	GKS for 59	64	97%	95% at 3 and 7 yrs	-	-	32%	New cranial nerve deficits: 0% New onset optic nerve dysfunction: 0%
Liscak ⁴³ , 2007	Retrospective / III / Therapeutic	GKS for 119	60	100%				1.5%	New cranial nerve deficits: 0% New onset optic nerve dysfunction: 0%
Mingione ³³ , 2006	Retrospective / III / Therapeutic	GKS for 92	47.9	92%	-	-	Margin dose <12 Gy	19.8%	New cranial nerve deficits: 0% New onset optic nerve dysfunction: 0%

Author , year	Study Design / Class / Classification Process	Intervention	Follow-up (months)	Tumor control rate	Progressive-free survival (%)	Favorable factor	Unfavorable factor	Hypopituitarism	Other complications
Picozzi ³¹ , 2005	Case-control study / II / Therapeutic	G1: obs for 68 G2: GKS for 51	G1: 41.6 G2: 40.6	-	At 5 yrs G1: 51.1% G2: 89.8%	-	-	-	-
Kuo ⁴⁷ , 2004	Retrospective / III / Therapeutic	GKS for 49	20.6	100%	-	-	-	-	-
Losa ⁴⁶ , 2004	Retrospective / III / Therapeutic	GKS for 54	41.1	96%	88.2% at 5 yrs	Higher radiation dose	-	12.5%, 8.6% 2.3% in hypogonadism, hypothyroidism, and hypoadrenalism	New cranial nerve deficits: 0% New onset optic nerve dysfunction: 0%
Muacevic ⁴⁵ , 2004	Retrospective / III / Therapeutic	GKS for 60	21.7	94%	95%, 90% at 3 yrs and 5 yrs	-	Low maximum dose	4%	-
Petrovich ⁴⁹ , 2003	Retrospective / III / Therapeutic	GKS for 56	36	100%	-	High margin dose	-	-	New cranial nerve deficits: 4% New onset optic nerve dysfunction: 0%

Author, year	Study Design / Class / Classification Process	Intervention	Follow-up (months)	Tumor control rate	Progressive-free survival (%)	Favorable factor	Unfavorable factor	Hypopituitarism	Other complications
Pollock ⁴⁸ , 2003	Retrospective / III / Therapeutic	GKS for 32	43	97%	97% at 2 yrs and 5 yrs	-	-	28%	New cranial nerve deficits: 0% New onset optic nerve dysfunction: 0%
Feigl ⁵² , 2002	Retrospective / III / Therapeutic	GKS for 61	55	94%	-	-	-	49%	-
Sheehan ⁵¹ , 2002	Retrospective / III / Therapeutic	GKS for 42	31.2	98%	-	-	-	0%	New cranial nerve deficits: 0% New onset optic nerve dysfunction: 0%
Wowers ⁵⁰ , 2002	Retrospective / III / Therapeutic	GKS for 44	57.7	95%	93% at 5 yrs	-	Low maximum dose	10%	-
Mokry ⁵³ , 1999	Retrospective / III / Therapeutic	GKS for 30	20.7	97%	-	-	-	20%	New cranial nerve deficits: 0% New onset optic nerve dysfunction: 0%
Lim ⁵⁴ , 1998	Retrospective / III / Therapeutic	GKS for 22	26.3	100%	-	-	-	-	-

GKS: gamma knife radiosurgery, yrs: years

Table 3: Evidence Detailing Conventional Radiotherapy and Fractionated Stereotactic Radiotherapy for Residual/Recurrent NFPA

Author, year	Study Design / Class / Classification Process	Intervention	Follow-Up (months)	Tumor control rate	Actuarial PFS (%)	Favorable factor	Unfavorable factor	Hypopituitarism	Other complications
Kopp ⁵⁹ , 2013	Retrospective / III / Therapeutic	FSRT for 16	63	100%	-	Initial GTV	-	-	-
Iwata ³⁷ , 2011	Retrospective / III / Therapeutic	Hypofractionated SRT for 94	33	-	98%	-	-	4.1%	New onset optic nerve dysfunction: 1%
Chang ⁶⁰ , 2008	Retrospective / III / Therapeutic	RT for 663	101	90.3%	93%, 87%, 81% at 5, 10, and 15 yrs	-	Cavernous sinus invasion, subtotal resection without RT	-	-
Losa ⁵⁵ , 2008	Case control study / II / Therapeutic	G1: absent tumor: 279 G2: residual tumor without RT: 76 G3: residual tumor with RT: 81	53	-	At 5 yrs G1: 87.1% G2: 39.2% G3: 100%	-	-	-	-

Author, year	Study Design / Class / Classification Process	Intervention	Follow-Up (months)	Tumor control rate	Actuarial PFS (%)	Favorable factor	Unfavorable factor	Hypopituitarism	Other complications
van den Bergh ⁵⁶ , 2007	Case control study / II / Therapeutic	G1: Surgery+ immediate post-op RT: 76 G2: Surgery only: 28	G1: 93 G2: 71	G1: 96% G2: 43%	At 5 and 10 yrs G1: 95%, 95% G2: 49%, 22%	-	-	-	-
Langsenlehner ⁶¹ , 2007	Retrospective / III / Therapeutic	RT for 61	180	95%	98.7%, 93.0%, 93.0% at 5, 10, 15 yrs	-	-	88%	Vascular complications: 4.5%
Minniti ⁶³ , 2006	Retrospective / III / Therapeutic	SRT (LINAC) for 67	32	-	99%, 98%, 98% at 1, 3, 5, yrs	-	-	22%	New onset optic nerve dysfunction: 1%
Selch ⁶² , 2006	Retrospective / III / Therapeutic	SRT for 33	32	100%	100% 100% at 2, 4 yrs	-	-	15%	No patient developed cranial nerve injury or second malignancy following treatment.
Paek ⁶⁴ , 2005	Retrospective / III / Therapeutic	SRT for 65	30	98.5%	98% at 5 yrs	-	-	6%	New onset optic nerve dysfunction: 3%
Park ⁵⁷ , 2004	Case control study / II / Therapeutic	G1: Immediate XRT for 44 G2: obs + XRT for 132	G1: 68 G2: 45	-	At 5, 10 yrs G1: 98%, 98% G2: 85%, 49%	-	-	-	-

Author, year	Study Design / Class / Classification Process	Intervention	Follow-Up (months)	Tumor control rate	Actuarial PFS (%)	Favorable factor	Unfavorable factor	Hypopituitarism	Other complications
Jalali ⁶⁶ , 2000	Retrospective / III / Therapeutic	SRT for 13	9	100%	100% at 1 and 2 yrs	-	-	0%	Permanent Visual impairment: 0%
Kokubo ⁶⁵ , 2000	Retrospective / III / Therapeutic	XRT for 22	126	100%	-	-	-	35% (panhypopituitarism)	New cranial nerve deficits: 0% New onset optic nerve dysfunction: 5%
Woolloons ⁵⁸ , 2000	Case control study / II / Therapeutic	G1: XRT for 50 G2: non-XRT for 22	64	G1: 74% G2: 54%	-	Complete tumor excision	-	-	-
Breen ⁶⁸ , 1998	Retrospective / III / Therapeutic	XRT for 120	108	87.5%	87.5%, 77.6%, 64.7% at 10, 20, and 30 yrs	Nononcocytic null cell adenoma	Oncocytoma	-	Optic and oculomotor neuropathy: 0.8% Radiation-induced neoplasms (meningioma and glioblastoma multiforme): 1.7%
Gittoes ⁶⁷ , 1998	Retrospective / III / Therapeutic	XRT for 126	90	-	93%, 93% at 10 and 15 yrs	-	-	-	-
Coke ⁶⁹ , 1997	Retrospective / III / Therapeutic	SRT for 14	10	100%	-	-	-	-	-
Zierhut ⁷⁰ , 1995	Retrospective / III / Therapeutic	XRT for 138	78	95%	-	-	-	27%	New onset optic nerve dysfunction: 1.5%

Author, year	Study Design / Class / Classification Process	Intervention	Follow-Up (months)	Tumor control rate	Actuarial PFS (%)	Favorable factor	Unfavorable factor	Hypopituitarism	Other complications
Tsang ⁷¹ , 1994	Retrospective / III / Therapeutic	XRT for 160	104	-	87% at 10 yrs	-	-	23%	New onset optic nerve dysfunction: 0%
Brada ⁷² , 1993	Retrospective / III / Therapeutic	XRT for 411	130	-	94%, 88% at 10 and 20 yrs	-	-	30% at 10 yrs	New onset optic nerve dysfunction: 1.5%
McCullough ⁷³ , 1991	Retrospective / III / Therapeutic	XRT for 105	140	-	95% at 10 yrs	-	-	-	-
Grigsby ⁷⁴ , 1989	Retrospective / III / Therapeutic	XRT for 121	94	-	89.9% at 10 yrs	-	-	-	New onset optic nerve dysfunction: 1.7%

FSRT: fractionated stereotactic radiotherapy, G: group, GTV: gross tumor volume, LINAC: linear acceleration, SRT: stereotactic radiotherapy, XRT: fractionated radiotherapy, yrs: years

APPENDIX A

Search Strategies

PubMed

1. Pituitary Neoplasms [Mesh] OR Adenoma [Mesh] OR Adenoma, Chromophobe [Mesh]
2. (microadenoma*[Title/Abstract] OR adenoma*[Title/Abstract] OR macroadenoma*[Title/Abstract] OR incidentaloma*[Title/Abstract] OR chromophobe*[Title/Abstract] OR transsphenoidal*[Title/Abstract])
3. (pituitary[Title/Abstract] OR hypophyse*[Title/Abstract] OR sellar[Title/Abstract] OR transsphenoidal[Title/Abstract])
4. #1 OR (#2 AND #3)
5. (residual[Title/Abstract] OR recurr*[Title/Abstract])
6. #4 AND #5
7. NOT Comment[pt] NOT Letter[pt]

Limit to English, Humans, publication date to 10/01/2014

Cochrane

1. MeSH descriptor Pituitary Neoplasms
2. MeSH descriptor Adenoma
3. 1 and 2
4. ((pituitary OR hypophyse* OR sellar) NEAR/4 (microadenoma* OR adenoma* OR macroadenoma* OR incidentaloma* or chromophobe*)):ti,ab,kw
5. 3 or 4 and (asymptomatic* OR nonfunction* OR non-function* OR nonsecret* OR non-secret* OR inactive OR null OR inert OR silent)